6 Pruritus and Dysesthesia

Sonja Ständer, Manuel P. Pereira, Elke Weisshaar and Jeffrey D. Bernhard

Chapter Contents

Epidemiology 110
Evaluation of the Patient 110
Pruritus in Dermatologic Disease 111
Dermatoses Induced by Pruritus-Associated Scratching or Rubbing 114
Pruritus in Specific Locations 116
Pruritus Variants 116
Pruritus in Systemic Disease 117
Pruritus in Pregnancy 120
Pharmacologic Pruritus 120
Psychogenic Pruritus 120
Neuropathic Etiologies of Pruritus and Dysesthesia 121
Treatment 124

INTRODUCTION

Pruritus can be defined as an unpleasant sensation that elicits a desire to scratch. The presumed biologic purpose of pruritus is to provoke scratching to remove a parasite or other harmful pruritogen. Pruritus is the most common skin-related symptom. It often arises from a primary cutaneous disorder but can be a manifestation of an underlying systemic disease in 15%–50% of affected individuals, especially when generalized[1,2]. Non-dermatologic conditions that can lead to generalized pruritus include hepatic, renal, or thyroid dysfunction; lymphoma, myeloproliferative neoplasms (e.g. polycythemia vera), and chronic lymphocytic leukemia; HIV or parasitic infections; and neuropsychiatric disorders (see Ch. 7).

A clinical classification scheme for chronic pruritus was proposed in 2007 by the International Forum for the Study of Itch[3]. In this system, there are three major groups of pruritus: (1) chronic pruritus of lesional (inflamed) skin; (2) chronic pruritus of non-lesional (non-inflamed) skin; and (3) chronic pruritus presenting with secondary scratch-induced lesions (e.g. prurigo nodularis, lichen simplex chronicus). Following initial evaluation, the etiology of the pruritus is categorized as dermatologic, systemic, neurologic, psychogenic, mixed, or other/unknown[3]. Such classification assists in planning further evaluation and treatment of the underlying disease (if possible) as well as the pruritus itself. Recent advances in our understanding of the mechanisms underlying chronic pruritus have led to the development of targeted therapies, and additional promising drugs are expected in the near future.

EPIDEMIOLOGY

It is assumed that all humans experience the sensation of pruritus at some point in their life, e.g. from insect bites (Fig. 6.1). However, relatively few studies have investigated the overall incidence and prevalence of pruritus. In a Norwegian population-based, cross-sectional study of self-reported skin morbidities, pruritus was the dominant symptom among adults, experienced within the past week by 9% of women and 7.5% of men[4]. A German population-based, cross-sectional study found that the self-reported point, 12-month, and lifetime prevalences of chronic pruritus (lasting ≥6 weeks) were 13.5%, 16%, and 22%, respectively[5]; in a follow-up cohort study, a 7% 12-month cumulative incidence of chronic pruritus was observed[6]. Women have a higher lifetime prevalence of chronic pruritus than men, and older adults are more frequently affected. Table 6.1 summarizes the prevalence of pruritus in various medical conditions[7].

EVALUATION OF THE PATIENT

A structured approach to the evaluation of patients with a chief complaint of pruritus is presented in Fig. 6.2. Pruritus is a subjective sensation, and currently its presence or severity cannot be assessed objectively. Thus, a thorough history that includes the patient's itch sensation plus a complete cutaneous examination for any evidence of skin lesions are important for correct diagnosis and allow assignment of the patient to one of the three clinical groups of pruritus (see above).

Fig. 6.1 Insect bites. Linear pruritic papules with central crusts demonstrating the "breakfast, lunch, and dinner" sign. *Courtesy Antonio Torrelo, MD.*

PREVALENCE OF PRURITUS IN SELECTED CONDITIONS	
Disorder	**Reported prevalence of pruritus**
Atopic dermatitis	100% (diagnostic criterion)
Lichen planus	~95%
Psoriasis	60%–95%
End-stage kidney disease on hemodialysis	25%–30%
Primary biliary cholangitis	80% (often the presenting symptom)
Hepatitis C viral infection	~15%
Cutaneous T cell lymphoma	60%–80% overall; >90% in Sézary syndrome
Polycythemia vera	30%–50%
Hodgkin lymphoma	≤30%
Non-Hodgkin lymphoma	≤10%
Leukemias	<5%
Herpes zoster	≤60%
Postherpetic neuralgia	≤30%
Pregnancy	~20%

Table 6.1 Prevalence of pruritus in selected conditions (see text).

Downloaded for Anonymous User (n/a) at Egyptian Knowledge Bank from ClinicalKey.com by Elsevier on March 10, 2024. For personal use only. No other uses without permission. Copyright ©2024. Elsevier Inc. All rights reserved.

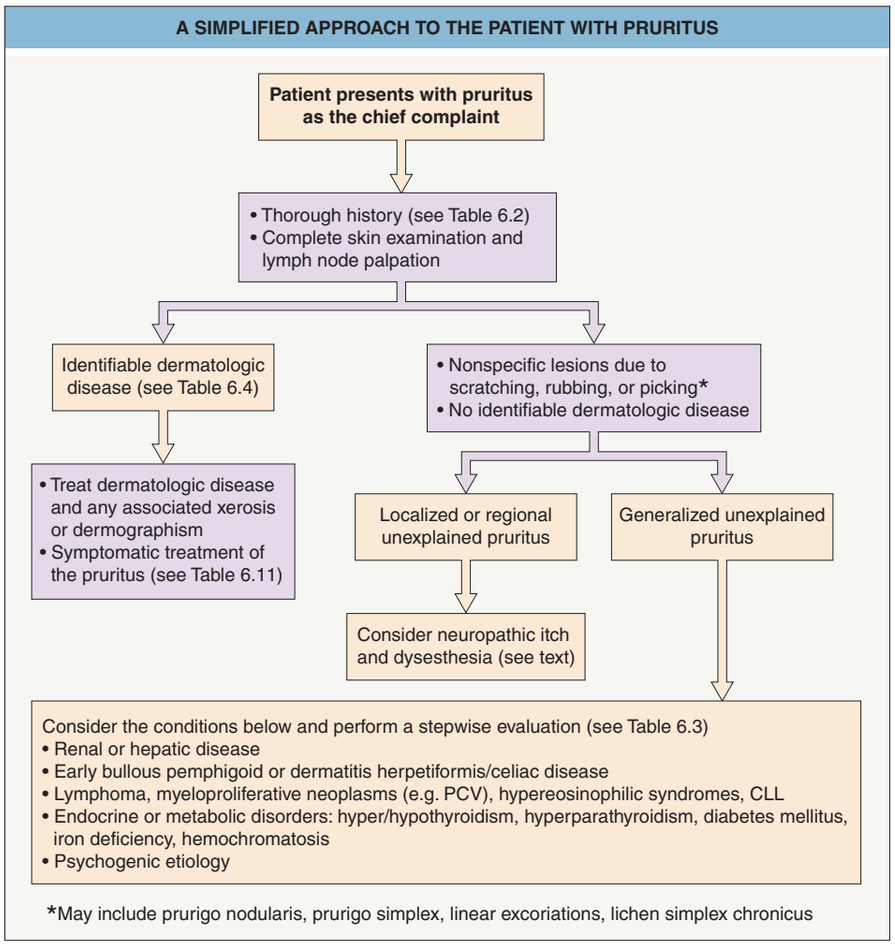

Fig. 6.2 A simplified approach to the patient with pruritus. CLL, chronic lymphocytic leukemia; PCV, polycythemia vera.

Patients with evidence of a particular skin condition should be treated accordingly, while those with no identifiable primary skin disease (i.e. an absence of or only secondary skin lesions) require further investigation to determine the etiology of their pruritus. Also, chronic pruritus can have multiple underlying factors, and a pruritic skin condition that has nonspecific clinical findings initially may over time develop diagnostic features. Therefore, longitudinal evaluation is essential.

History

A precise history may provide insight into the patient's disease processes. In addition to the patient's spontaneous description, specific questions regarding the onset, location, duration, and nature of the pruritus can help to determine its cause (Table 6.2)[8]. The use of standardized instruments to assess itch intensity (e.g. a numerical rating scale) and impairment of quality of life (e.g. ItchyQol) is recommended[9]. A medical and medication history should also be obtained. Although chronic, progressive, generalized pruritus without primary skin lesions raises suspicion of an underlying systemic disease, no particular clinical characteristics reliably predict the likelihood of a systemic etiology[8].

Examination

Careful and complete examination of the skin, nails, scalp, hair, mucous membranes (e.g. oral, conjunctival), and anogenital area at the initial visit is recommended. The morphology and distribution of primary lesions and secondary changes (e.g. excoriations, crusts, lichenification) should be assessed, with particular attention to xerosis, the presence of dermographism (Fig. 6.3), and skin signs of systemic diseases (see Ch. 53). Lesions on the mid upper back suggest a primary skin disease, since this difficult-to-reach area is typically spared (the "butterfly sign") in patients with skin lesions secondary to scratching (see Fig. 6.5A). However, this region can be accessed with "back-scratching" devices.

The examination should include palpation of major peripheral lymph node groups (e.g. cervical, supraclavicular, axillary, inguinal), especially in those with no obvious primary inflammatory skin disease. Together with a general physical examination performed by the patient's primary care physician, this may disclose an undiagnosed extracutaneous disease (e.g. lymphoma) in individuals with pruritus of unknown etiology[8].

Laboratory Investigation and Radiographic Imaging

In the setting of pruritus of unknown etiology, a stepwise approach to laboratory tests and other investigations (e.g. radiographic imaging) is recommended (Table 6.3). Microscopic examination of skin scrapings for signs of scabies or a fungal infection as well as examination of stool samples for parasites can also be considered. Biopsies of representative skin lesions, even if nonspecific clinically, are occasionally informative, and direct immunofluorescence studies of perilesional skin or normal-appearing skin (in the vicinity of lesions if present) may point to a specific dermatologic disease such as bullous pemphigoid or dermatitis herpetiformis, respectively. Radiographic examinations may be performed to exclude an underlying malignancy or other systemic condition as well as peripheral nerve impingement when neuropathic itch is suspected[8].

PRURITUS IN DERMATOLOGIC DISEASE

This section focuses on the sensation of pruritus in selected skin diseases where this symptom is a prominent feature. A more comprehensive discussion of the diseases mentioned and the many additional dermatoses in which pruritus is a characteristic feature (Table 6.4) may be found in other chapters.

Inflammatory Dermatoses

Urticaria

Urticaria is often intensely pruritic and can also produce stinging or prickling sensations. Early lesions and small superficial wheals are

Downloaded for Anonymous User (n/a) at Egyptian Knowledge Bank from ClinicalKey.com by Elsevier on March 10, 2024. For personal use only. No other uses without permission. Copyright ©2024. Elsevier Inc. All rights reserved.

DESCRIPTIVE FEATURES OF THE PRURITUS AND ADDITIONAL PATIENT HISTORY
Questions to ask regarding the pruritus
• WHEN did it start? *Duration:* days, weeks, months, years
• WHERE did it start? WHERE is it now? *Location*: localized or generalized; unilateral or bilateral; within lesional (inflamed) skin or non-lesional (non-inflamed) skin
• HOW did it develop? *Onset*: abrupt, gradual, progressive, prior history of pruritic episodes
• HOW does it feel? *Nature:* prickling, crawling, burning, stinging
• HOW intense is it? *Severity:* on numerical ranking scale (1–10); mild, moderate, severe; interference with normal activities or sleep
• HOW often do you feel it? *Time course:* intermittent, continuous, cyclical, nocturnal
• WHAT makes it worse? *Provoking/aggravating factors:* heat, cold, water, air, exercise, occupation, hobbies
• WHAT makes it better? *Itch relief:* cold, heat, scratching/rubbing/hurting, cool/hot showering
• WHAT do you think is the cause? *Patient's theory of pruritus etiology*
Additional patient history
• Skin care, bathing habits, exposure to irritants
• Medications (including topical agents): prescribed, over-the-counter; duration of use and relationship to onset of pruritus
• Use of nicotine, alcohol, and recreational/illicit drugs
• Allergies (known and suspected): drugs, airborne, food, contact
• Atopic history: atopic dermatitis, allergic rhinoconjunctivitis, asthma
• Past and present medical history: thyroid, liver, or renal dysfunction; other systemic diseases; psychological disease; surgeries or accidents
• Family history: atopy, skin disease, similar pruritic conditions
• Occupation, hobbies, personal stress
• Household and personal contacts; pets and their care
• Dietary habits
• Sexual history
• Travel history
• Prior diagnoses made by physician or patient

Table 6.2 Descriptive features of the pruritus and additional patient history.

LABORATORY AND RADIOGRAPHIC EVALUATION IN PATIENTS WITH PRURITUS OF UNKNOWN ETIOLOGY
Basic initial evaluation
• Complete blood count (CBC) with differential and platelet count
• Erythrocyte sedimentation rate (ESR), C-reactive protein (CRP)
• Creatinine, blood urea nitrogen (BUN)
• Liver transaminases, alkaline phosphatase, bilirubin
• Lactate dehydrogenase (LDH)
• Thyroid stimulating hormone (TSH)
• Fasting plasma glucose
• Serum ferritin, serum iron, and total iron binding capacity
Possible additional evaluation
Skin biopsy
• Routine histology (if skin lesions are present)
• Direct immunofluorescence studies*
Other laboratory tests
• Serum total and/or allergen-specific IgE
• Serum protein electrophoresis, serum immunofixation electrophoresis
• Viral hepatitis panel (including hepatitis B and C viruses); HIV testing
• Parathyroid function (calcium, phosphate, parathyroid hormone levels)
• Serum tryptase
• Anti-BP180 and anti-BP230 bullous pemphigoid IgG antibodies; anti-tissue transglutaminase IgA antibody
• Anti-mitochondrial and anti-smooth muscle antibodies
• Stool for ova/parasites
Radiographic studies
• Chest X-ray or CT scan
• Abdominal and pelvic ultrasonography or CT scan
• Lymph node ultrasonography
• Spinal X-ray or MRI (for regional pruritus)
Other investigations
• Patch testing
• Prick testing for major atopy and relevant occupational allergens
• Age-appropriate cancer screening (in conjunction with primary care physician)
• If hydroxyethyl starch (HES)-induced pruritus is suspected, electron microscopy of a biopsy sample from normal-appearing skin
*Biopsy perilesional skin or normal-appearing skin (in vicinity of lesions if present) to assess for bullous pemphigoid and dermatitis herpetiformis, respectively.

Table 6.3 Laboratory and radiographic evaluation in patients with pruritus of unknown etiology. A general physical examination should also be performed by the patient's primary care physician. Selection of particular tests beyond the basic initial evaluation is based upon the patient's history, physical examination findings, and pruritus severity. The results of initial testing can also help to direct further evaluation[8].

Fig. 6.3 Dermographism. Linear streaks of urticaria induced by scratching the skin. Assessment for dermographism should be performed in all patients with pruritus.

particularly symptomatic[1]. Histamine plays a primary role in the pruritus of urticaria, and H1-receptor antagonists usually decrease or eliminate this sensation as well as the wheals themselves[10]. Several other mediators are involved in the pathophysiology of urticaria, and interleukin (IL)-31 levels correlate with itch intensity[11]. When refractory to higher doses of antihistamines, omalizumab, and cyclosporine represent alternative treatments for urticaria (see Ch. 18).

Atopic dermatitis

Pruritus is such an important aspect of atopic dermatitis that "the diagnosis of active atopic dermatitis cannot be made if there is no history of pruritus"[12] (see Ch. 12). The itch sensation typically comes in "attacks", which may be severe and significantly impact quality of life[13]. Often, pruritus is the first indication of a disease flare. Moreover, scratching as a response to itch leads to excoriations and lichenification, which represent additional clinical features of atopic dermatitis[14]. Pruritus can be provoked by exposure to aeroallergens or ingestion of foods to which the patient is sensitized as well as non-immunologic triggers, including emotional stress, overheating, perspiration, and contact with rough fabrics or even air (atmokinesis)[15] (Fig. 6.4). Although most affected children experience worsening of symptoms during the winter, others have exacerbations primarily during the summer[16]. Of note, pruritus may persist after resolution of inflammatory skin lesions.

The minimal effectiveness of antihistamines in alleviating the itch of atopic dermatitis indicates that histamine is probably not the predominant mediator of the pruritic sensation[17–19]. Rather, the benefit of antihistamines in atopic dermatitis is most likely due to their sedative effects. Type 2 cytokines such as IL-4, IL-13, IL-31, and thymic stromal lymphopoietin play a key role in the inflammation of atopic dermatitis. As a result, therapies that target Th2 signaling via IL-4/-13 (e.g. dupilumab, tralokinumab, lebrikizumab), IL-31 (nemolizumab), or Janus kinase (JAK) 1/2 have anti-pruritic effects[14].

Other mediators and receptors with possible roles in the pruritus of atopic dermatitis include neuropeptides (e.g. substance P, calcitonin gene-related peptide [CGRP]), neurotrophic factors (e.g. nerve growth factor [NGF], artemin [causes warmth-provoked itching]), epidermal opioid receptors (downregulated), and endothelin-1[14,18,19]. In addition, itch transmission results from kallikrein-related peptidase and mast

Downloaded for Anonymous User (n/a) at Egyptian Knowledge Bank from ClinicalKey.com by Elsevier on March 10, 2024. For personal use only. No other uses without permission. Copyright ©2024. Elsevier Inc. All rights reserved.

PRIMARY DERMATOLOGIC CONDITIONS ASSOCIATED WITH PRURITUS	
Cause	**Dermatologic disease**
Inflammation	• Atopic dermatitis • Allergic or irritant contact dermatitis • Seborrheic dermatitis, especially of the scalp • Stasis dermatitis • Psoriasis • Parapsoriasis • Pityriasis rubra pilaris • Lichen planus and its variants • Urticaria, dermographism • Mastocytosis • Papular urticaria, urticarial dermatitis • Drug eruptions, e.g. morbilliform • Polymorphous light eruption, actinic prurigo, chronic actinic dermatitis • Bullous diseases, e.g. DH, BP • Polymorphic eruption of pregnancy (PEP) • Eosinophilic folliculitis • Dermatomyositis • Prurigo pigmentosa • Lichen sclerosus • Graft-versus-host disease
Infestation/ bites & stings	• Scabies • Pediculosis • Arthropod bites
Infections	• Bacterial infections, e.g. folliculitis • Viral infections, e.g. varicella • Fungal infections, e.g. inflammatory tinea • Parasitic infections, e.g. schistosomal cercarial dermatitis
Neoplastic	• Cutaneous T cell lymphoma, e.g. mycosis fungoides, Sézary syndrome
Genetic/ nevoid	• Darier disease and Hailey–Hailey disease • Ichthyoses, e.g. Netherton, Sjögren–Larsson, and peeling skin syndromes • Pruriginosa subtype of dominant dystrophic EB • Porphyrias, e.g. porphyria cutanea tarda and erythropoietic protoporphyria • Inflammatory linear verrucous epidermal nevus (ILVEN) • Large/giant congenital melanocytic nevi, occasionally, especially in bulky lesions with neural differentiation • Multiple intestinal atresia, early-onset IBD, and combined immunodeficiency (*TTC7A* mutations)
Other	• Xerosis, eczema craquelé • Primary cutaneous amyloidosis (macular, lichenoid) • Postburn pruritus • Scar-associated pruritus • Radiation-associated pruritus • Fiberglass dermatitis (see Ch. 16)

Table 6.4 Primary dermatologic conditions associated with pruritus. BP, bullous pemphigoid; DH, dermatitis herpetiformis; EB, epidermolysis bullosa; IBD, inflammatory bowel disease.

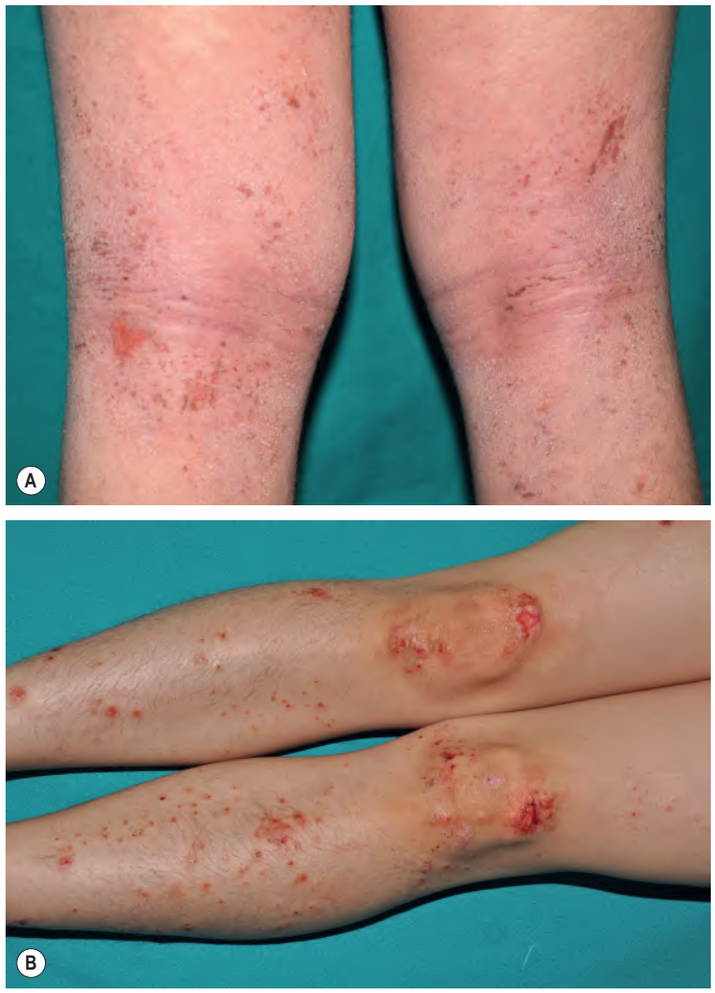

Fig. 6.4 Atopic dermatitis. A Excoriated eczematous plaques in the popliteal fossae, a classic flexural location for atopic dermatitis. **B** Prurigo simplex, prurigo nodularis-like lesions, and angulated ulcerations; the latter two are primarily on the knees. *Courtesy Antonio Torrelo, MD.*

cell tryptase binding to protease-activated receptors (PAR-2; see Ch. 5). In atopic patients, morphologic alterations of cutaneous nerves and neuronal sensitization may also contribute to an increased itch sensation and even the perception of painful stimuli as itch[20].

Psoriasis

Although not traditionally regarded as a pruritic disease, studies have shown that up to 60%–95% of psoriasis patients suffer from pruritus, with xerosis, heat, sweating, and emotional stress serving as exacerbating factors[21]. While lesions on the scalp, back, and legs are most often pruritic, generalized pruritus can occur in plaque-type as well as erythrodermic and pustular psoriasis[21]. Patients frequently describe the pruritus as having tickling, crawling, and burning components, and antihistamines rarely provide relief. Although the pathophysiology of psoriatic itch is still largely unknown, it is thought to be multifactorial and a variety of itch mediators (e.g. substance P, NGF, protein gene product 9.5, CGRP, neuropeptide Y, IL-2, opioid receptors) have been implicated[21]. Coadministration of β-blockers, angiotensin-converting enzyme (ACE) inhibitors, or antacids may be associated with the development of psoriatic itch[22]. Successful treatment of psoriasis can reduce associated pruritus (see Ch. 8)[21,23].

Infestations

Scabies

In patients with scabies, pruritus can be localized or generalized, and it may have a burning component. It is usually more intense at night and typically spares the head. The pruritus usually begins 3–6 weeks after a first-time infestation, and within a few days in subsequent infestations; multiple family members are often affected (see Ch. 84). The itch reflects various components of the immune response against mites, eggs, and scybala[1]. Bacterial superinfection and eczematization of skin lesions may also contribute to itch in patients with scabies[24].

Pediculosis (lice)

Pruritus at the primary sites of infestation (e.g. scalp, groin) is a clue to the diagnosis of head and pubic lice (see Ch. 84). Generalized pruritus is characteristic of body lice but can also occur with other forms of lice infestation[1].

Cutaneous T Cell Lymphoma (CTCL)

Pruritus affects >60% of patients with CTCL, with an increased frequency and intensity in those with later-stage disease, especially Sézary syndrome (>90% of patients) and folliculotropic mycosis fungoides (MF)[25,26]. A variant of Sézary syndrome presenting with

Downloaded for Anonymous User (n/a) at Egyptian Knowledge Bank from ClinicalKey.com by Elsevier on March 10, 2024. For personal use only. No other uses without permission. Copyright ©2024. Elsevier Inc. All rights reserved.

generalized pruritus and minimal or no clinically evident skin disease has also been described[27]. Pruritus significantly reduces the quality of life in CTCL patients[28], and it has been associated with an increased risk of disease progression and death.

IL-31 is a putative mediator of itch in CTCL, especially in late-stage disease, and lower serum IL-31 levels have been observed in association with reduced pruritus following treatment with histone deacetylase inhibitors and mogamulizumab (anti-CC-chemokine receptor type-4 antibody)[29–31]. Other possible mediators of CTCL-related itch include IL-4, IL-5, IL-10, IL-13, substance P, NGF, endogenous opioids, and visfatin[31].

Treatment strategies for severe pruritus not responsive to disease-directed therapy in CTCL patients include gabapentin (900–2400 mg daily in divided doses) and/or mirtazapine (7.5–15 mg nightly) as well as opioid antagonists (e.g. naltrexone 50–150 mg daily)[8]. Aprepitant has also been reported to relieve intractable pruritus in patients with Sézary syndrome and other forms of CTCL, suggesting a role for neurokinin-1 (NK1) receptors and substance P in CTCL-related itch[32]. However, in a recent randomized controlled trial (RCT), aprepitant failed to demonstrate an antipruritic effect compared to placebo in patients with Sézary syndrome[33].

DERMATOSES INDUCED BY PRURITUS-ASSOCIATED SCRATCHING OR RUBBING

Prurigo Nodularis

Prurigo nodularis is associated with chronic itch (i.e. lasting ≥6 weeks), where skin lesions are produced by repetitive, focused scratching or picking of the skin[34]. Neuronal sensitization and the development of an itch–scratch cycle contribute to disease chronicity[35]. Prurigo nodularis most often occurs in adults, especially women, but can affect any age group, including children and adolescents with an atopic diathesis[36].

Multiple pruritic papulonodules are most commonly observed on the extensor aspects of the extremities, and their distribution is usually symmetric. The upper back, lumbosacral region, and buttocks may also be involved, but the difficult-to-reach mid upper back is classically spared ("butterfly sign") (Fig. 6.5A). Flexural areas as well as the face and groin are often spared.

The firm, dome-shaped papulonodules have varying degrees of central scale, crust, erosion, or ulceration (Fig. 6.5A–C). The color ranges from skin-toned to erythematous to brown, with hyperpigmentation often seen in individuals with more darkly pigmented skin (see Fig. 6.5C). Lesions can develop a verrucous or fissured surface and lichenification of adjacent skin may be observed. When crusted smaller papules are the predominant finding, the term prurigo simplex is sometimes utilized.

The etiology of the underlying pruritus varies and may include atopic dermatitis (up to 50% of patients), xerosis, another skin disorder, or a systemic disease (e.g. hepatic or renal dysfunction)[35]. Psychological afflictions (e.g. emotional distress) and neuropsychiatric conditions (e.g. obsessive–compulsive disorder, autism spectrum disorders) can also lead to repetitive scratching. Occasionally, prurigo nodularis is associated with an underlying lymphoma and less often solid tumor malignancies[37]. The clinical differential diagnosis of prurigo nodularis may include pemphigoid nodularis (Fig. 6.6), hypertrophic lichen planus, hypertrophic lupus erythematosus, scabietic nodules, persistent insect bite reactions, the pruriginous type of dominant dystrophic epidermolysis bullosa, and neoplasms such as multiple keratoacanthomas or granular cell tumors.

Histologically, there is marked epidermal hyperplasia and thick, compact hyperkeratosis[38]. Keratinocyte atypia is absent, and small areas of erosion or ulceration may be seen. Fibrosis of the papillary dermis with vertically arranged collagen fibers, increased numbers of fibroblasts and capillaries, and a perivascular or interstitial mixed inflammatory infiltrate represent additional findings.

Possibly as a result of intense scratching, pruriginous lesions demonstrate hypertrophy and an increased density of dermal nerve fibers. In contrast, the number of nerve fibers within the epidermis is reduced. There is increased expression of substance P, CGRP, and NGF receptors by the dermal nerve fibers and prominent NGF immunoreactivity in lesional dermis. The dermal neuronal hyperplasia and epidermal "small fiber neuropathy" may play a pathogenic role in perpetuating the pruritus of prurigo nodularis[20,39]. Additionally, proinflammatory

Fig. 6.5 Prurigo nodularis. A Numerous excoriated nodules on the back, buttocks, and arms as well as linear excoriations. Note the sparing of the mid upper back ("butterfly sign"). **B** Nodules and plaques in various stages on the knees of a patient with atopic dermatitis. **C** Firm, hyperpigmented papulonodules on the extensor forearm. *A, Courtesy Luis Requena; B, Courtesy Antonio Torrelo, MD; C, Courtesy Ronald P. Rapini, MD.*

Downloaded for Anonymous User (n/a) at Egyptian Knowledge Bank from ClinicalKey.com by Elsevier on March 10, 2024. For personal use only. No other uses without permission. Copyright ©2024. Elsevier Inc. All rights reserved.

Fig. 6.6 Bullous pemphigoid presenting as pruritus with lesions of prurigo simplex. Bullous pemphigoid is often intensely pruritic and may not present with intact vesiculo-bullae. *Courtesy Department of Dermatology, Medical University of Graz.*

mediators such as IL-31 are upregulated in pruriginous lesions and contribute to neurogenic inflammation.

Treatment of prurigo nodularis is usually difficult and typically requires a multifaceted approach, which should be individualized depending on etiologic factors and the extent of disease[40]. Any underlying conditions (e.g. atopic dermatitis, chronic kidney disease, cholestasis) should be identified and treated if possible. Ideally, significantly reducing the pruritus would break the itch–scratch cycle, eventually leading to healing of the lesions; however, this is often not possible, especially when there is a psychological underpinning. Topical antipruritic agents (e.g. menthol, pramoxine, polidocanol) and oral antihistamines may help to decrease itch intensity. The former can be applied repeatedly as a "substitute" for scratching, and a sedating antihistamine at bedtime may be beneficial for sleep disturbances.

The skin lesions may respond to superpotent topical corticosteroids under occlusion, corticosteroid-impregnated tape, intralesional corticosteroids, phototherapy (e.g. narrowband or broadband UVB, psoralen plus UVA [PUVA]), or excimer laser treatment. Other topical treatments with potential benefit include capsaicin (0.025%–0.1% 4–6 times daily, applied locally), calcipotriene (calcipotriol), and calcineurin inhibitors. Based upon RCTs in which ~45%–50% of patients with prurigo nodularis achieved clear or almost clear skin after 24 weeks of therapy, dupilumab was FDA approved for this indication[40a]. The IL-31 receptor inhibitor nemolizumab was also found in RCTs to significantly reduce pruritus and cutaneous lesions in adults with prurigo nodularis[41].

Improvement of prurigo nodularis with gabapentinoids (e.g. gabapentin, pregabalin), μ-opioid receptor antagonists (e.g. naloxone, naltrexone), or combined μ-opioid receptor antagonist/κ-opioid receptor agonists (e.g. nalbuphine) has been described. Systemic immunosuppressive drugs such as cyclosporine or methotrexate may be of benefit, especially in patients in which the inflammatory component of the disease predominates. Treatment directed toward any underlying compulsive behavior is important. Selective serotonin reuptake inhibitors (SSRIs) and tricyclic antidepressants have both been employed successfully, especially when a component of depression is present. Thalidomide (50–200 mg daily) has been reported to be highly effective for patients with recalcitrant prurigo nodularis, although its use is limited by teratogenicity and the potentially irreversible side effect of peripheral neuropathy.

Lichen Simplex Chronicus

In lichen simplex chronicus (LSC), there is epidermal hypertrophy secondary to chronic, habitual rubbing or scratching of localized areas of skin. Lesions of LSC are broader and thinner than those of prurigo nodularis. LSC is most frequently observed in adults and is relatively uncommon in children, with the exception of lichenified lesions in atopic dermatitis.

Fig. 6.7 Lichen simplex chronicus. A Lichenified pink plaque on the ankle of a young man. **B** Note the increased skin markings in this hyperpigmented plaque on the posterior neck. *B, Courtesy Ronald P. Rapini, MD.*

LSC is characterized by well-defined plaques exhibiting exaggerated skin lines (lichenification) with a "leathery" appearance, coalescing papules, hyperpigmentation, and varying degrees of erythema. Lesions may be solitary or multiple, with a predilection for the posterolateral neck, occipital scalp, anogenital region (e.g. scrotum, vulva), shins, ankles, and dorsal aspects of the hands, feet, and forearms (Fig. 6.7). Predisposing factors include xerosis, atopy, psoriasis, stasis dermatitis, anxiety, obsessive–compulsive disorder, localized neuropathic itch, and pruritus related to systemic disease.

The clinical differential diagnosis may include lichen amyloidosis and hypertrophic lichen planus, both of which present with chronic pruritic plaques favoring the shins. *Lichen ruber moniliformis* is a historic condition that presents with rows of papules and cord-like fibrotic bands, which may be both pruritic and painful. Histologic features of LSC are similar to those of prurigo nodularis (see above), with compact hyperkeratosis, acanthosis with irregular elongation of rete ridges, hypergranulosis, and vertically oriented collagen bundles in the papillary dermis.

Like prurigo nodularis, lesions of LSC itch spontaneously, which leads to an "itch–rub/scratch–itch" cycle that often makes it resistant to treatment. Underlying pruritic disorders should be identified and treated if possible. Management strategies are similar to those described for prurigo nodularis (see above), with topical corticosteroids (± occlusion) and intralesional corticosteroids as the mainstays of therapy. Repeated application of a hydrocolloid dressing can lead to improvement. Informal insight-oriented psychotherapy and application

Downloaded for Anonymous User (n/a) at Egyptian Knowledge Bank from ClinicalKey.com by Elsevier on March 10, 2024. For personal use only. No other uses without permission. Copyright ©2024. Elsevier Inc. All rights reserved.

of topical antipruritic agents as "substitutes" for rubbing/scratching may be of benefit. Use of topical lidocaine 5% or capsaicin 8% patches, licensed for the treatment of postherpetic neuralgia, may be helpful in recalcitrant cases. Additional treatments may include antihistamines, gabapentinoids, antidepressants, phototherapy, transcutaneous electrical stimulation, and focused ultrasound[42].

PRURITUS IN SPECIFIC LOCATIONS

Scalp Pruritus

Skin disorders involving the scalp (e.g. seborrheic dermatitis, psoriasis, folliculitis, lichen planopilaris, dermatomyositis) may present with pruritus localized to this area. However, scalp pruritus also occurs in the absence of any objective changes including in the setting of neuropathic disorders (e.g. small-fiber neuropathy, postherpetic neuralgia) or psychogenic itch[43]. Trigger factors should be avoided and any underlying cause treated if possible. Topical corticosteroids and antipruritic agents have been employed with inconsistent efficacy[44].

Anogenital Pruritus

Pruritus ani

Pruritus localized to the anus and perianal skin occurs in 1%–5% of the general population, with a male : female ratio of ~4 : 1[45]. The onset is typically insidious, and symptoms may be present for weeks or years before patients seek medical attention.

Pruritus ani can be primary (idiopathic) or secondary in nature. Primary pruritus ani is defined as pruritus in the absence of any apparent cutaneous, anorectal, or colonic disorder; it accounts for 25%–95% of reported cases, depending upon the series. Possible causes include dietary factors such as poor personal hygiene and psychiatric disorders. Secondary pruritus ani has an identifiable etiology such as chronic diarrhea, fecal incontinence/anal seepage, hemorrhoids, anal fissures or fistulas, rectal prolapse, primary cutaneous disorders (e.g. psoriasis, lichen sclerosus, seborrheic dermatitis, allergic contact dermatitis), sexually transmitted diseases, other infections, infestations (e.g. pinworms), previous radiation therapy or trauma, and neoplasms (e.g. anal cancer)[45]. Pruritus ani (as well as pruritus vulvae or scroti) can also be neuropathic in origin and be due to compression or irritation of lumbosacral nerves from prolapsed intervertebral discs, vertebral body fractures, or osteophytic processes.

Findings on physical examination range from normal-appearing skin or mild perianal erythema to severe irritation with crusting, lichenification, and erosion or ulceration. Histologically, a nonspecific, chronic dermatitis is usually seen, but specific dermatoses (e.g. lichen sclerosus) and neoplastic disorders (e.g. extramammary Paget disease) can be excluded.

Evaluation includes a thorough history, complete cutaneous and general physical examination, and psychiatric screening. The latter is of importance considering that anxiety and depression may be aggravating factors for pruritus ani. Patch testing should be considered to exclude allergic contact dermatitis. Rectosigmoidoscopy and/or colonoscopy may be necessary, especially in patients with recalcitrant pruritus ani, in order to detect underlying conditions ranging from hemorrhoids to cancer. The possibility of pinworm infection should be considered, particularly in affected children[46]. In patients receiving chronic antibiotic therapy who have liquid stools with a pH of 8–10, *Lactobacillus* replacement therapy is recommended.

While secondary pruritus ani usually improves with treatment of the underlying disorder, management of primary disease can be very challenging. Mild cases often respond to elimination of irritants and triggers, sitz baths (e.g. with astringents such as black tea), cool compresses, and meticulous hygiene using water-moistened, fragrance-free toilet paper or a bidet. The area is then dried with blotting or a fan, with avoidance of rubbing and alkaline soaps[46] (see Ch. 153). Application of zinc oxide paste can help to protect the skin from further irritation and friction.

A mild corticosteroid cream (class 6 or 7) is often effective in controlling symptoms. However, with greater disease severity or the presence of lichenification, more potent topical corticosteroids and prolonged treatment may be required, raising the risk of cutaneous atrophy. Topical calcineurin inhibitors, including use on a rotational basis with topical corticosteroids, may be helpful when longer courses of therapy are necessary[47].

Pruritus vulvae and scroti

These common disorders, which may be incapacitating and emotionally disturbing, are solely psychogenic in only 1%–10% of patients[1]. Like pruritus ani, patients with pruritus of the vulva or scrotum typically complain of symptoms that are worse at night, and repeated rubbing or scratching leads to lichenification. The evaluation, differential diagnosis, and treatment options are similar to those for pruritus ani.

Acute pruritus of the vulva or scrotum is often related to infections such as candidiasis or scabies, but allergic or irritant contact dermatitis should also be considered. *Chronic* pruritus in these sites may be caused by dermatoses (e.g. psoriasis, atopic dermatitis, lichen sclerosus, lichen planus, LSC), malignancy (e.g. extramammary Paget disease, squamous cell carcinoma), or atrophic vulvovaginitis[46]. Scrotal pruritus secondary to lumbosacral radiculopathy has also been described[48]. In general, irritation of sensitive genital skin from cleansing and toilet habits needs to be addressed, as well as treatment of any identifiable underlying cause.

PRURITUS VARIANTS

Aquagenic Pruritus

Aquagenic pruritus is usually secondary to a systemic disease (e.g. polycythemia vera) or another skin disorder (e.g. urticaria, dermographism; Table 6.5), whereas primary (idiopathic) aquagenic pruritus is relatively uncommon. Aquagenic pruritus presents with prickling, tingling, burning, or stinging sensations within 30 minutes of water contact, irrespective of its temperature or salinity, and lasts for up to 2 hours[1]. Typically, symptoms begin on the lower extremities and then generalize, with sparing of the head, palms, soles, and mucosae[49]; on examination, specific skin lesions are not seen. The pathologic mechanism is unknown, although elevated dermal and epidermal levels of acetylcholine, histamine, serotonin, and prostaglandin E_2 have been described[1].

Treatment of aquagenic pruritus is difficult. Aspirin (300–500 mg daily) was of benefit in one RCT. Treatment with narrowband or broadband UVB or PUVA may also be effective. Based upon case reports and case series, alkalization of bath water with baking soda, capsaicin cream (0.025%–0.1% applied 3–6 times daily for ≥4 weeks), and systemic agents including β-blockers (e.g. propranolol, atenolol), clonidine, ibuprofen prior to bathing, pregabalin, H2-blockers, opioid receptor antagonists, antidepressants, and interferon-α may be helpful[8]. In secondary forms of aquagenic pruritus, treatments should target any underlying condition, e.g. antihistamines for dermographism.

DIFFERENTIAL DIAGNOSIS OF PRURITUS OR PRICKLING SENSATIONS PROVOKED BY WATER CONTACT
Disease-associated skin findings typically evident at time of visit
• Polycythemia vera (ruddy complexion; see text) • Mastocytosis (cutaneous lesions, positive Darier's sign) • Hypereosinophilic syndrome (cutaneous lesions in >50% of patients) • Hemochromatosis (diffuse hyperpigmentation)
Urticaria by history and/or challenge
• Dermographism • Cold urticaria • Cholinergic urticaria (with hot water exposure) • Aquagenic urticaria
Skin findings (other than those due to scratching) typically absent
• Hodgkin lymphoma • Myelodysplastic syndromes • Essential thrombocythemia • Testosterone-induced erythrocytosis • Drug-related (e.g. antimalarials, bupropion, clomipramine) • Aquagenic pruritus of the elderly (xerosis may be subtle) • Primary (idiopathic) aquagenic pruritus

Table 6.5 Differential diagnosis of pruritus or prickling sensations provoked by water contact. A possible relationship with lactose intolerance in a subset of patients has also been reported.

Downloaded for Anonymous User (n/a) at Egyptian Knowledge Bank from ClinicalKey.com by Elsevier on March 10, 2024. For personal use only. No other uses without permission. Copyright ©2024. Elsevier Inc. All rights reserved.

Pruritus in Scars

Scar remodeling can last from 6 months to 2 years. Pruritus associated with wound healing is common and usually resolves over time, but it is occasionally prolonged, especially in hypertrophic or keloidal scarring. The pruritus in immature or abnormal scars is most likely a consequence of physical and chemical stimuli as well as nerve regeneration. Physical stimuli include direct mechanical stimulation of nerve endings during scar remodeling. Histamine, vasoactive peptides (e.g. kinins), and prostaglandins E1/E2 may account for a "chemogenic" pruritus. Nerve regeneration occurs in all healing wounds, and a disproportionate number of thinly myelinated and unmyelinated C-fibers in immature or abnormal scars may contribute to increased itch perception. The observation of abnormalities in small nerve fiber morphology and function within keloids has raised the possibility of a small nerve fiber neuropathy[50].

Therapy includes emollients, topical and intralesional corticosteroids, cryotherapy, brachytherapy, and silicone gel sheets. Oral antihistamines do not have a significant benefit. Relief of pain and pruritus associated with giant keloids was observed with oral pentoxifylline (400 mg 2–3 times daily)[51].

Post-Thermal Burn Pruritus

Approximately 85% of patients with burns experience pruritus during the healing phase, particularly when the burns involve the limbs[52]. A gradual decrease in pruritus usually occurs, but it may persist for years. Both neuropathic and pruritogenic mechanisms are thought to contribute to the development of itch after a burn[53]. Reported predictors of pruritus include a deep dermal burn injury, female sex, and psychological distress[54]. Morphine therapy may also contribute to postburn pruritus. Emollients, topical anesthetics (e.g. lidocaine/prilocaine) or doxepin, massage therapy, bathing in oiled water or with colloidal oatmeal, extracorporeal shockwave therapy, and botulinum toxin may be of benefit[55,56]. In an RCT, oral gabapentin was found to be more effective than cetirizine for postburn pruritus[57]. Other systemic therapy options include ondansetron, opioid modulators, and antidepressants[53,58].

Fiberglass Dermatitis

Fiberglass exposure is common in individuals who work in manufacturing or construction. Deposition of fiberglass particles on the skin may provoke severe pruritus, sometimes in the absence of visible skin lesions (see Ch. 16). Involvement of the hands and other non-covered sites such as the arms, face, and upper trunk is typical. Cutaneous findings vary and include erythema, papules, vesicles, excoriations, and lichenification. The clinical presentation may resemble scabies, eczematous dermatitis, folliculitis, or urticaria. Tolerance often develops with prolonged fiberglass exposure[59].

PRURITUS IN SYSTEMIC DISEASE

Chronic Kidney Disease-Associated Pruritus (Renal Pruritus)

Pruritus is a frequent symptom in patients with advanced chronic (not acute) kidney disease, especially those requiring dialysis[7,60]. Although the term "uremic pruritus" is used synonymously, it incorrectly implies that the symptom is secondary to elevated serum urea levels. Nowadays, chronic kidney disease-associated pruritus (CKD-aP), rather than renal pruritus, is the preferred term.

CKD-aP may be localized or generalized, and the intensity and distribution often vary over time. Prurigo nodularis and other secondary skin lesions can develop due to scratching, rubbing, or picking the skin. CKD-aP represents an independent predictor of mortality in dialysis patients and is associated with sleep disturbances, depression, and impaired quality of life[61].

In general, the occurrence of CKD-aP is not associated with sex, race, duration of dialysis, or etiology of the kidney disease[7]; it is rare in children but otherwise does not correlate with age. From 25% to 45% of hemodialysis patients suffer from pruritus[7,62]; a decrease in pruritus frequency over the past few decades likely reflects improvements in dialysis procedures, such as utilization of high-permeability rather than conventional hemodialysis[63]. Patients receiving continuous ambulatory peritoneal dialysis (CAPD) appear to be slightly less or equally affected by pruritus compared to those on hemodialysis[1]. In patients receiving standard thrice weekly hemodialysis, pruritus usually peaks in the evening after 2 days without dialysis, is relatively high during dialysis, and is lowest the following day[64,65].

The etiology of CKD-aP is poorly understood. The role of mast cells and histamine is controversial, with no relationship between plasma histamine levels and the severity of pruritus[66]. This finding is supported by the failure of antihistamine therapy in most affected individuals. Another possible explanation for CKD-aP is an accumulation of compounds that cross the dialysis membranes slowly[1].

Parathyroid gland activity is commonly increased in chronic kidney disease, and dramatic relief of pruritus after subtotal parathyroidectomy has been reported in some patients[1]. However, although higher serum levels of calcium, phosphate, and parathyroid hormone (PTH) have been detected in dialysis patients with pruritus than in those without pruritus, no correlation between degree of pruritus and PTH levels has been observed[67]. Furthermore, studies have failed to demonstrate PTH immunoreactivity within the skin, PTH does not produce pruritus when injected intradermally, and pruritus is not always present in uremic patients with hyperparathyroidism.

Although dry, scaly skin is common in patients with chronic kidney disease (Fig. 6.8), the presence of pruritus does not correlate with xerosis, stratum corneum hydration, or sweat secretion[68,69]. Peripheral neuropathy affects up to 65% of patients who receive dialysis, raising the possibility that pruritus may be a manifestation of a neuropathy. Loss of itch-*inhibiting* CGRP-expressing neurons in the papillary dermis has been observed in CKD-aP patients[70]. Opioids could potentially play a role, as they accumulate with renal failure. However, this accumulation is unrelated to the duration of disease and levels are unaltered by hemodialysis[1]. A recent study found a decrease of κ-opioid receptors in the skin of hemodialysis patients with pruritus, suggesting a role of the peripheral opioid system in renal itch[68]. It has also been suggested that an immunologic alteration characterized by a proinflammatory pattern is involved in the pathogenesis of CKD-aP, and elevated serum IL-31 levels have been reported[69]. Lastly, higher serum aluminum levels have also been associated with pruritus in hemodialysis patients[71].

The management of CKD-aP is often very challenging, and currently available therapeutic options are outlined in Table 6.6. Xerosis should be addressed with gentle skin care and emollients (see Table 6.11). Treatment with topical γ-linolenic acid, pramoxine, corticosteroids, tacrolimus, or capsaicin may be helpful. Antihistamines typically have only marginal efficacy, with improvement related primarily to their sedative effects[1].

Fig. 6.8 Xerosis and scratching in a patient with end-stage kidney disease undergoing hemodialysis. There are a few papules of acquired perforating dermatosis admixed with the scratch marks. *Courtesy Jean L. Bolognia, MD.*

Downloaded for Anonymous User (n/a) at Egyptian Knowledge Bank from ClinicalKey.com by Elsevier on March 10, 2024. For personal use only. No other uses without permission. Copyright ©2024. Elsevier Inc. All rights reserved.

THERAPEUTIC LADDER FOR RENAL PRURITUS	
First-line	Gabapentin (100–300 mg po*) (1) Pregabalin (25–75 mg po*) (1) Difelikefalin† (0.5 mcg/kg iv*) (1)
Second-line	UVB narrowband or broadband phototherapy (alone or in combination with other treatments) (1)
Third-line	Naltrexone‡ (25–50 mg po daily) (2) Naloxone‡ (0.002–0.2 mcg/kg body weight/min iv × 8 hours for 3–5 days, repeated monthly) (3) Nalfurafine† (2.5–5 mcg po or iv*) (1)
Localized itch	Capsaicin cream (0.025% 3–5 times daily) (2)
Additional options	*Topical* γ-linolenic acid (2.2% cream 4 times daily) (1) Pramoxine (1% lotion 2–4 times daily) (1) Cromolyn sodium (4% cream twice daily) (1) *Systemic* Activated charcoal (6 g po daily) (1) Montelukast (10 mg po daily) (1) Cromolyn sodium (100–135 mg po 3–4 times daily) (1) Doxepin (10–20 mg po daily) (1) Ketotifen (1–2 mg po daily) (2) Sertraline (25–100 mg po daily) (2) Pentoxifylline (600 mg iv*) (3) Lidocaine (200 mg iv daily) (3) Erythropoietin (36 U/kg sc 3 times weekly) (3) Cholestyramine (4–16 g po daily in divided doses) (2)

*Typically administered post-hemodialysis; in non-dialysis-dependent patients, dose adjustments for gabapentinoids are made based upon degree of renal impairment.
†κ-opioid receptor agonist; nalfurafine is available in Japan.
‡μ-opioid receptor antagonist.

Table 6.6 Therapeutic ladder for renal pruritus[136]. Additional interventions include addressing underlying xerosis, evaluating the quality of dialysis (see text), and assessing serum parathyroid hormone (PTH) level, with treatment of hyperparathyroidism if present. The combined μ-opioid receptor antagonist/κ-opioid receptor agonist nalbuphine was found to have benefit in an RCT, but the extended release oral formulation used in the study is not currently available. General measures for pruritus management are summarized in Table 6.11. Key to evidence-based support: (1) prospective controlled trial; (2) retrospective study or large case series; (3) small case series or individual case reports. iv, intravenously; po, per os; sc, subcutaneously.

In patients with CKD-aP, serum PTH levels should be assessed and hyperparathyroidism treated if present. The quality of dialysis should also be evaluated to ensure that the Kt/V (urea clearance [K] multiplied by dialysis time [t] divided by volume of urea distribution [V]) is ≥1.2. If itch persists, gabapentin (100–300 mg orally) after each dialysis session can be tried; low-dose pregabalin may be equally effective[72]. Phototherapy, especially broadband or narrowband UVB, represents an alternative or adjunctive modality. Difelikefalin, a peripherally acting κ-opioid receptor agonist, was shown in an RCT to significantly reduce itch intensity in hemodialysis patients and is now an FDA/EMA-approved treatment for CKD-aP[73]. Nalfurafine (available in Japan) is another κ-opioid receptor agonist that was found to be effective in multicenter controlled studies[74]. The μ-opioid receptor antagonist naltrexone (25–100 mg orally daily) represents an additional option. Even in patients with intractable CKD-aP, renal transplantation generally leads to resolution of itch.

Cholestatic Pruritus

Nearly any liver disease can present with pruritus, but the most commonly associated entities are primary biliary cholangitis (primary biliary cirrhosis), primary sclerosing cholangitis, obstructive choledocholithiasis, carcinoma of the bile duct, cholestasis (may also be drug-induced), chronic hepatitis C viral infection, and other forms of viral hepatitis[1]. Pruritus in these settings tends to be generalized, migratory, and not relieved by scratching. It tends to be more pronounced at night and is typically worse on the hands and feet (especially the palms and soles) as well as body regions constricted by clothing. In patients with chronic cholestasis, pruritus can be an early symptom that develops years before any other manifestation of the liver disease[1].

The exact etiology of cholestatic pruritus is unknown. MRGPRX4 (Mas-related G-protein coupled receptor member X4), a bile acid receptor expressed in sensory neurons, is involved in itch transmission and may represent a therapeutic target.[75,76] However, elevated serum levels of bile acids are not always associated with pruritus, and in patients with severe cholestasis the development of hepatocellular failure tends to result in spontaneous cessation of pruritus[77]. Increased opioidergic neurotransmission or neuromodulation in the CNS is also hypothesized to contribute to cholestatic pruritus[78].

Other studies have provided evidence that lysophosphatidic acid (LPA), a neuronal activator, and autotaxin (ATX, lysophospholipase D), the enzyme responsible for production of LPA from lysophosphatidylcholine, play significant roles in cholestatic pruritus[79]. Unlike other putative mediators, ATX levels correlate with the intensity of itch in patients with cholestasis[77]. However, the factors presumably present in the enterohepatic circulation that are responsible for induction of ATX expression remain to be determined[80,81].

The disease underlying cholestatic pruritus should be treated if possible, such as gallstone removal, drug withdrawal, and therapy for chronic hepatitis C infection with direct-acting antiviral agents. A stepwise approach to the treatment of cholestatic pruritus is provided in Table 6.7[77,81]. In intrahepatic cholestasis of pregnancy (see Ch. 27), ursodeoxycholic acid (UDCA) significantly reduces itch and serum bile acid levels, probably due to improvement of hepatobiliary secretion, and it represents first-line therapy[82]. Although UCDA is also used in other cholestatic conditions, itch has not been studied as the primary endpoint. The ileal bile acid transporter inhibitors odevixibat and maralixibat are FDA-approved to treat cholestatic pruritus in patients with progressive familial intrahepatic cholestasis and Alagille syndrome, respectively[83,84]. The recommended first-line treatment for other forms of cholestatic pruritus is the anion exchange resin cholestyramine, which binds bile acids in the small intestine and results in their fecal excretion[85]. Rifampin represents a second-line option and may work by reducing ATX expression on a transcriptional level[86]. Opioid antagonists (e.g. naltrexone, naloxone) and the SSRI sertraline can also have antipruritic effects in cholestatic itch[87–89]. Fibrates, phototherapy, albumin dialysis, and plasmapheresis are additional treatment options[85]. Ultimately, liver transplantation for end-stage liver failure can improve symptoms.

Hematologic Pruritus

Significant pruritus can occur in association with a number of hematologic diseases, especially hypereosinophilic syndromes (see Ch. 25) and myeloproliferative neoplasms such as polycythemia vera and Hodgkin lymphoma, and less often essential thrombocythemia. Occasionally, patients with myelodysplastic syndrome have significant pruritus.

Iron deficiency

In patients with iron deficiency plus generalized or localized pruritus, especially of the perianal or vulvar region, improvement with iron supplementation has been described[1,90]. Of note, iron deficiency can be a sign of polycythemia vera and other malignancies or systemic diseases that themselves may cause pruritus. In addition to laboratory confirmation, the etiology of the iron deficiency should be determined, including exclusion of a gastrointestinal source of blood loss.

Polycythemia vera

Aquagenic pruritus may precede the development of polycythemia vera by several years and eventually affects ~30%–50% of polycythemia vera patients. Thus, this diagnosis should be considered in all patients with aquagenic pruritus (see above). Additional cutaneous findings include a ruddy facial complexion, erythema of the hands and feet, and conjunctival injection. Approximately 97% of patients with polycythemia vera have a somatic mutation (V617F) in the Janus kinase 2 gene (*JAK2*) that results in constitutive activation and agonist hypersensitivity in basophils, which may have a pathogenic role in their aquagenic pruritus. Platelet aggregation has also been suggested as a possible underlying mechanism, with release of serotonin and other pruritogenic factors such as histamine. In RCTs, the JAK 1/2 inhibitor ruxolitinib led to rapid improvement of polycythemia vera and its associated pruritus[91,92]. Other treatment options include hydroxyurea, aspirin (300 mg daily), UVB or PUVA phototherapy (reports of success), SSRIs (effective in small series), interferon-α-2b (approved therapy with good efficacy), and oral H1- or H2-receptor antagonists (variable results)[1,93].

Downloaded for Anonymous User (n/a) at Egyptian Knowledge Bank from ClinicalKey.com by Elsevier on March 10, 2024. For personal use only. No other uses without permission. Copyright ©2024. Elsevier Inc. All rights reserved.

TREATMENT OPTIONS FOR HEPATIC OR CHOLESTATIC PRURITUS		
	Treatment and dosing	**Specific indications**
First-line	Cholestyramine (4–16 g po daily, with 4-hour interval if taking other medications) (1)	Cholestatic pruritus
	Odevixibat* (40–120 mcg po daily, maximum 6 mg daily) (1)	Progressive familial intrahepatic cholestasis
	Maralixibat* (190–380 mcg/kg po daily) (1)	Alagille syndrome
	Ursodeoxycholic acid (13–15 mg/kg or 1 g po daily) (1)	Intrahepatic cholestasis of pregnancy
Second-line	Rifampin (150–600 mg po daily) (1)	
Third-line	Bezafibrate (400 mg po daily) (1)	Primary biliary cholangitis, primary sclerosing cholangitis
Fourth-line	Naltrexone† (25–50 mg po daily) (1) Naloxone† (0.002–0.2 mcg/kg body weight/min iv × 8 hours for 3–5 days, repeated monthly) (1) Gabapentin (300–3600 mg daily) (3) Pregabalin (75–600 mg po daily) (3)	
Fifth-line	Sertraline (75–100 mg po daily) (1)	
Additional options	Phototherapy with narrowband or broadband UVB (3) Nalmefene† (escalating twice daily po dose: 2 mg [day 1], 5 mg [day 2], 10 mg [day 3], then 20 mg; further increases as needed, maximum of 120 mg) (1) Nalfurafine‡ (2.5–5 mcg po daily) (1) Butorphanol nasal spray¶ (1–2 mg [1–2 puffs] daily) (3) Paroxetine (10–20 mg po daily) (3) Dronabinol (5 mg po nightly) (3) Phenobarbital (2–5 mg/kg po daily) (3) Lidocaine 100 mg iv daily (1) Thalidomide 100 mg po daily (3)	
Procedural interventions	Nasobiliary drainage (3) Plasmapheresis, plasma separation and anion adsorption (3) Extracorporeal albumin dialysis (e.g. MARS – molecular adsorbents recirculating system) (3)	

*Ileal bile acid transporter inhibitor.
†μ-opioid receptor antagonist.
‡κ-opioid receptor agonist; nalfurafine is available in Japan.
¶Combined κ-opioid receptor agonist and μ-opioid receptor antagonist.

Table 6.7 Treatment options for hepatic or cholestatic pruritus[136]. Antihistamines have limited benefit other than their sedating properties. Gabapentin did not have a therapeutic advantage over placebo in a controlled study. Ileal bile transporter inhibition with linerixibat was shown to be of benefit for primary biliary cholangitis in an RCT. General measures for pruritus management are summarized in Table 6.11. Potential adverse effects of rifampin include hepatitis, hemolytic anemia, and renal failure, necessitating periodic laboratory monitoring in patients with cholestasis. Potential adverse effects of bezafibrate include hepatic toxicity, rhabdomyolysis, and osteoporosis. Key to evidence-based support: (1) prospective controlled trial; (2) retrospective study or large case series; (3) small case series or individual case reports. iv, intravenously; po, per os.

Pruritus and Malignancy

Virtually any malignancy can induce pruritus, but the precise relationship between cancer and this symptom is unclear. In 2014, a special interest group of the International Forum on the Study of Itch[94] defined "paraneoplastic itch" as "a systemic reaction to the presence of a tumor or a hematological malignancy, neither induced by the local presence of cancer cells nor by tumor therapy". They noted that the itch usually disappears with remission of the neoplasm and returns with a disease relapse.

Paraneoplastic itch is most frequent with myeloproliferative neoplasms (e.g. polycythemia vera > essential thrombocythemia), lymphoma (Hodgkin > non-Hodgkin), and cancers of the liver or biliary system[91]. A population-based cohort study found that patients with chronic pruritus without concomitant skin findings (n = 8744; mean age, 61 years) had 2- and 3.7-fold increased risks of an incident hematologic or bile duct malignancy, respectively[92]. Another study found a 1-year absolute risk of cancer of 1.6% in patients with pruritus[95]. In pediatric patients, itch is most often associated with hematologic malignancies[96]. Thus, persistent unexplained pruritus or failure of generalized pruritus to respond to conventional therapy should warrant evaluation for an underlying malignancy, including a complete blood count and hepatic panel as well as a thorough review of systems and physical examination[10,94].

Paraneoplastic pruritus can occur in advanced disease or represent an early sign, which is sometimes present for several years prior to diagnosis. However, the intensity and extent of pruritus do not generally correlate with the extent of tumor involvement[1]. Proposed mechanisms of tumor-associated pruritus include toxic products from necrotic tumor cells entering the systemic circulation, production of chemical mediators of pruritus by the tumor, allergic reactions to tumor-specific antigens, increased proteolytic activity, and histamine release[8]. Pruritus can also be a symptom of malignancies that obstruct the biliary tree (e.g. carcinoma of the head of the pancreas or bile duct) or involve the brain ("central" pruritus)[8]. In addition, pruritus may develop due to treatment with surgery, radiotherapy, cytotoxic chemotherapy, targeted tumor therapy[94], or immunotherapy[97].

Treatment of the underlying malignancy is the most effective measure. In refractory cases, or when the tumor is not treatable, therapeutic options include antidepressants (e.g. paroxetine, mirtazapine), gabapentinoids, opioid modulators, NK1 receptor antagonists, and histone deacetylase inhibitors[8,98].

Hodgkin lymphoma

Up to 30% of patients with Hodgkin lymphoma experience pruritus. It is usually generalized and classically manifests at night in association with chills and sweating[1,8]. Severe, persistent pruritus is predictive of a poor prognosis, and return of this symptom may portend tumor recurrence. It has been proposed that pruritus should be added to the list of the "B symptoms" in this disease[1].

Factors contributing to pruritus in Hodgkin lymphoma may include eosinophilia and release of histamine (from basophils), leukopeptidases, or bradykinin. Hepatic involvement by the lymphoma may occasionally play a role. Production of IL-5 by Reed–Sternberg cells can lead to eosinophilia, but whether the eosinophil count correlates with the degree of pruritus is unclear. While the pruritus usually resolves following successful treatment of the lymphoma, based upon case reports and series, phototherapy, cimetidine, carbamazepine, mirtazapine, oral corticosteroids, and NK1 receptor antagonists may lead to some improvement[8,93].

Downloaded for Anonymous User (n/a) at Egyptian Knowledge Bank from ClinicalKey.com by Elsevier on March 10, 2024. For personal use only. No other uses without permission. Copyright ©2024. Elsevier Inc. All rights reserved.

Non-Hodgkin lymphoma

Pruritus is generally less prevalent in non-Hodgkin lymphoma than in Hodgkin lymphoma. Up to 10% of patients with non-Hodgkin lymphoma suffer from pruritus at some time during their disease course, often with improvement after successful therapy.

Leukemia

Pruritus is not a common symptom in patients with leukemia, but when it occurs, it is usually generalized. Chronic lymphocytic leukemia (CLL) and hypereosinophilic syndromes, which include patients with eosinophilic leukemia and other hematologic malignancies (see Ch. 25), are most often associated with pruritus. In addition, patients with CLL can develop exaggerated reactions to insect bites (see Ch. 33). Leukemia cutis may produce localized symptoms that include pruritus[10].

Endocrine Pruritus

Thyroid disease

Severe generalized pruritus may be a presenting symptom of hyperthyroidism. The cause is not known, but it is postulated to result from a direct effect of thyroid hormone on the skin[1]. Localized or generalized pruritus may also be seen in patients with hypothyroidism, but not as frequently. The skin in individuals with hypothyroidism is often dry, which can lead to asteatotic eczema accompanied by pruritus.

Diabetes mellitus

Generalized pruritus is a fairly common symptom of diabetes mellitus, with itch often first developing on the back[99]. Diabetic polyneuropathy is characteristically associated with pain as well as burning or prickling sensations, but it can also present with pruritus that starts on the feet and lower legs[99].

Pruritus in HIV Infection

Severe, treatment-resistant pruritus can be seen in HIV-infected individuals, and a possible correlation between intractable pruritus and increased HIV viral load has been observed[100]. Immunologic parameters associated with pruritus in HIV patients include markedly elevated IgE levels, peripheral hypereosinophilia, and a Th2-type cytokine profile.

HIV-infected individuals may develop a number of pruritic dermatoses such as pruritic papular eruption, eosinophilic folliculitis, severe seborrheic dermatitis, psoriasis, scabies, insect bite reactions, drug eruptions, xerosis, and acquired ichthyosis (see Ch. 78). Kaposi sarcoma lesions are occasionally pruritic. Patients with HIV infection may also have other causes of pruritus, such as chronic kidney disease, liver disease, and non-Hodgkin lymphoma and they can develop prurigo nodularis[101].

Treatment should be directed at any underlying dermatoses that can be identified (see above). Topical corticosteroids and antihistamines can be used symptomatically; antihistamines with anti-eosinophilic potential (e.g. cetirizine) may be more effective. UVB is an additional therapeutic option and is considered to be safe in HIV-infected individuals[102]. Although antiretroviral therapy (ART) can lead to improvement in several pruritic dermatologic diseases, a variety of infectious, inflammatory, and neoplastic skin conditions may flare when ART is started (immune reconstitution inflammatory syndrome; see Ch. 78)[101]. Thalidomide (100–300 mg daily) is used to treat pruritus and prurigo nodularis in patients with HIV infection and AIDS, as it is not an immunosuppressant[10,103].

PRURITUS IN PREGNANCY

Approximately 20% of pregnant women experience pruritus. This symptom can have multiple etiologies in a pregnant patient[104] and is discussed in Chapter 27.

PHARMACOLOGIC PRURITUS

Virtually any drug can cause a skin reaction that is associated with pruritus[1]. Pruritic drug reactions most often present as morbilliform or urticarial eruptions (see Ch. 21). Occasionally, however, pruritus is the predominant manifestation with an absence of skin findings (Table 6.8)[105,106]. Some medication effects (e.g. hepatotoxicity) that can lead to pruritus have a relatively long latency period. The primary goal is to identify and discontinue the offending drug, with supportive antipruritic therapy as needed (see Table 6.11).

COMMON PHARMACOLOGIC ETIOLOGIES OF PRURITUS	
Pathomechanism	**Medication(s)**
Cholestasis	Erythromycin estolate, estrogens (including oral contraceptives), captopril, sulfonamides, chlorpromazine
Hepatotoxicity	Acetaminophen, anabolic steroids (including testosterone), isoniazid, minocycline, amoxicillin–clavulanic acid, halothane, phenytoin, sulfonamides
Xerosis	Retinoids, β-blockers, calcium channel blockers, hydrochlorothiazide, tamoxifen, busulfan, clofibrate
Phototoxicity	8-Methoxypsoralen
Neurologic	Methamphetamine, tramadol, codeine, cocaine, morphine*,†, butorphanol*, fentanyl*
Increased serotonin signaling	Selective serotonin reuptake inhibitors (e.g. sertraline, fluoxetine)
Increased bradykinin levels‡	Angiotensin-converting enzyme (ACE) inhibitors
Increased leukotriene levels	Nonsteroidal anti-inflammatory drugs (NSAIDs)
Histamine analogue	Betahistine
MRGPR¶ stimulation	Chloroquine (pruritus may be generalized, localized to the hands/feet, or aquagenic; most common in individuals of African descent)
T cell activation due to CTLA-4, PD-1, or PD-L1 inhibition	Ipilimumab, nivolumab, pembrolizumab, cemiplimab, atezolizumab, avelumab, durvalumab
EGFR inhibition	Cetuximab, panitumumab, erlotinib, gefitinib, afatinib, osimertinib
Selective BRAF or MEK inhibition	Dabrafenib, encorafenib, vemurafenib; binimetinib, cobimetinib, trametinib
Other tyrosine kinase inhibition	Sorafenib (especially scalp pruritus), imatinib, dasatinib, nilotinib (see Table 21.16)
Deposition	Hydroxyethyl starch
Idiopathic	Clonidine, lithium, bleomycin, gold salts

*Pruritus is more likely with intrathecal/epidural than systemic administration.
†Also causes non-immunologic release of histamine from mast cells.
‡Pruritus may precede development of angioedema.
¶MAS-related G protein-coupled receptor expressed by epidermal C-nerve fibers.

Table 6.8 Common pharmacologic etiologies of pruritus[137–141]. Itch may also occur as a direct effect of interleukin 2 therapy. CTLA-4, cytotoxic T lymphocyte-associated antigen 4; EGFR, epidermal growth factor receptor; PD-1, programmed cell death protein 1.

PSYCHOGENIC PRURITUS

Generalized pruritus can be associated with anxiety disorders, depression, anorexia, and even psychoses (e.g. delusional infestation; see Ch. 7). In true psychogenic pruritus, patients present with a purely sensory complaint (pruritus) without evidence of a delusional component, primary skin disease, or underlying medical condition. It is rare and must be separated from excoriation (skin-picking) disorder, in which a patient creates cutaneous lesions without pre-existing pruritus. The intensity of psychogenic pruritus tends to parallel the emotional state and is often exaggerated[10]. No primary lesions are seen, and secondary lesions range from lichenification to excoriations. Although the patient's sleep pattern is usually uninterrupted, sedative antipruritics (e.g. doxepin) may be utilized as therapy because topical agents alone are rarely effective. Consultation with a psychiatrist is recommended.

Downloaded for Anonymous User (n/a) at Egyptian Knowledge Bank from ClinicalKey.com by Elsevier on March 10, 2024. For personal use only. No other uses without permission. Copyright ©2024. Elsevier Inc. All rights reserved.

NEUROPATHIC ETIOLOGIES OF PRURITUS AND DYSESTHESIA

A dysesthesia is defined as an unpleasant abnormal skin sensation, such as tingling, burning, numbness, or pruritus; it can be spontaneous or evoked and may result from abnormalities in the central or peripheral nervous system. Dysesthesias, including pruritus, are usually localized or regional in distribution and can affect almost any site. For dysesthesias related to disorders of the CNS, the location of the abnormality is more important than its cause. In other words, a stroke, tumor, or multiple sclerosis plaque in the same region of the brain will generate similar neurologic signs and symptoms[107].

Neuropathic pruritus most often results from damage, compression, or irritation affecting a nerve or group of nerves[3]. These neuropathies typically present with localized pruritus and secondary skin lesions due to repeated rubbing or scratching in a circumscribed area supplied by the afflicted nerve(s) (Fig. 6.9A). Pruritus may occasionally spread beyond the initial site, likely due to sensitization mechanisms. Pruritus of neurogenic origin occurs without neuronal damage, such as increased endogenous μ-opioids leading to disinhibition of itch.

Sensory (Mono)Neuropathies with Pruritus and Dysesthesia

Sensory (mono)neuropathies that are most often brought to the attention of dermatologists are notalgia paresthetica and brachioradial pruritus. Less often, symptoms of meralgia, cheiralgia, or digitalgia paresthetica require dermatologic assessment (see Fig. 6.9). Secondary skin lesions, if present, include excoriations, crusted papules, hyperpigmentation, and lichenification; these findings are localized to the area of dysesthesias that corresponds to the receptive field of one or a few sensory nerves[108].

Treatment with topical capsaicin (0.025%–0.1%) 3–6 times daily for ≥4–6 weeks or a capsaicin 8% patch (applied for one hour under physician supervision; may be repeated every 3 months, if needed) may be helpful. Other treatment options include topical anesthetics (e.g. lidocaine, pramoxine), topical corticosteroids, oral gabapentin/pregabalin, and acupuncture.

Notalgia paresthetica

Notalgia paresthetica is a common condition in adults that is characterized by focal, intense pruritus of the upper back, especially over the medial scapular borders. Most evidence suggests that notalgia paresthetica represents a sensory neuropathy. The posterior rami of T2–T6 pursue a right-angle course through the multifidus spinae muscle that extends along the vertebral column, potentially predisposing these nerves to entrapment and injury (Fig. 6.9C). Degenerative changes of the spine corresponding to the affected dermatome(s) are present in a subset of patients[109]. Notalgia paresthetica can also represent a sign of multiple endocrine neoplasia type 2A (Sipple syndrome; see Ch. 63), especially if the onset is during childhood or adolescence.

In addition to itch, patients may occasionally report pain, dysesthesias, paresthesias, or hyperesthesias[109]. A characteristic finding on physical examination is a hyperpigmented patch due to chronic rubbing of the affected area. Dermal melanophages are evident histologically, and there is considerable overlap with macular amyloidosis (see Ch. 47).

Treatment of notalgia paresthetica is often difficult. Topical antipruritics (e.g. pramoxine) and corticosteroids are typically ineffective. Topical capsaicin may provide temporary benefit, and oxcarbazepine and gabapentin have demonstrated variable improvement in case series. Oral difelikefalin is under investigation, but currently it requires intravenous administration. Additional case reports have shown benefits from botulinum toxin A, but in an RCT, intradermal botulinum toxin A injection showed no benefit over placebo. If spinal pathology is suspected, management considerations include spinal imaging, referral for orthopedic or neurologic consultation; and treatment of the underlying cause with modalities such as physical therapy (e.g. rolling on a massage ball), nerve blocks, and surgical decompression.

Brachioradial pruritus

This chronic sensory neuropathy of the radial dorsal antebrachial cutaneous nerve is characterized by intermittent pruritus or burning

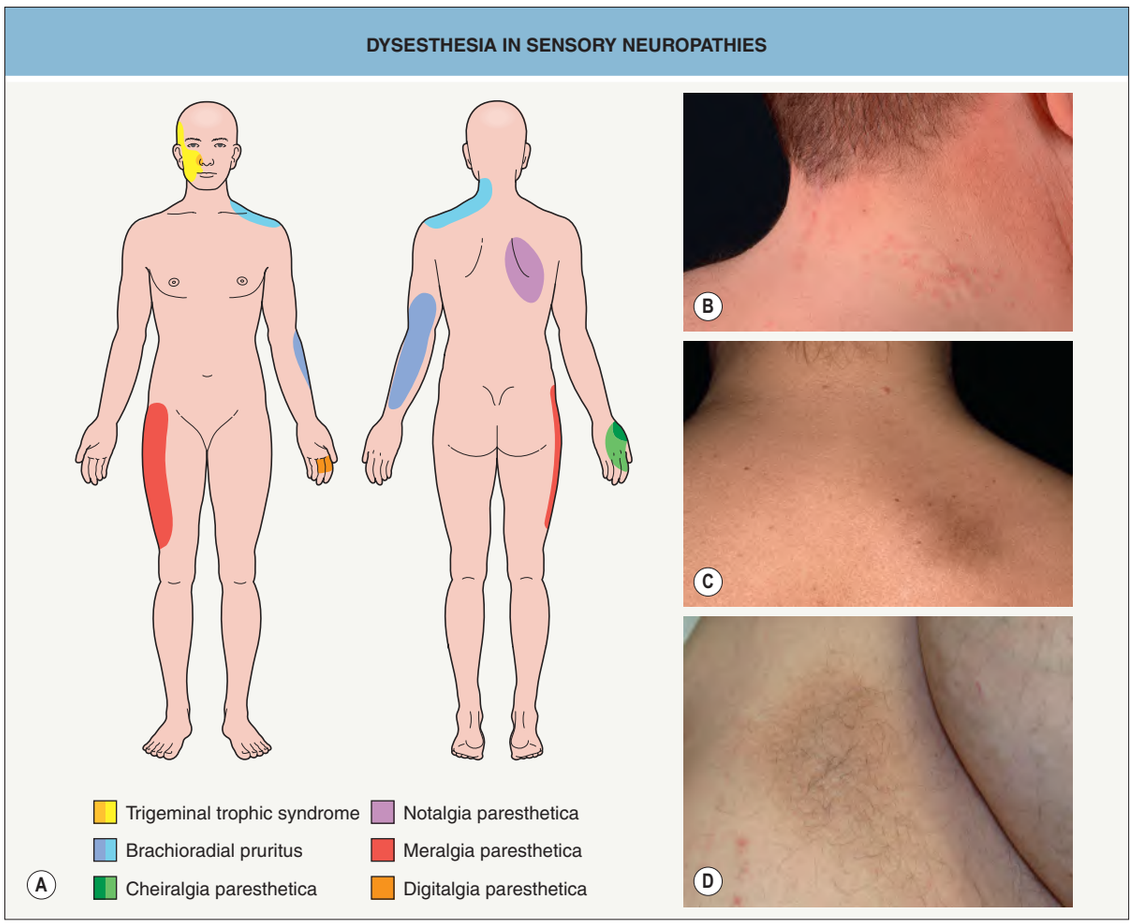

Fig. 6.9 Dysesthesia in sensory neuropathies. A Distribution of dysesthesia in selected neuropathic conditions. The names for these entities come from Greek terms, e.g. *notos* = back, *meros* = thigh, *cheiron* = hand, *algos* = pain. Darker shades indicate more common areas of involvement. **B** Secondary skin lesions on the right neck in a patient with cervical osteoarthropathy. **C** Classic notalgia paresthetica with hyperpigmentation on the right upper back at the medial scapular border. **D** Meralgia paresthetica presenting as hyperpigmentation and lichenification in a discrete area of dysesthesia on the anterior thigh. *A, Courtesy Karynne O. Duncan, MD; C, Courtesy Lorenzo Cerroni, MD.*

Downloaded for Anonymous User (n/a) at Egyptian Knowledge Bank from ClinicalKey.com by Elsevier on March 10, 2024. For personal use only. No other uses without permission. Copyright ©2024. Elsevier Inc. All rights reserved.

pain on the dorsolateral aspects of the forearms and elbows; there is sometimes more extensive involvement (e.g. of the shoulder and neck; Fig. 6.9B)[110]. More than half of patients have radiographic evidence of degenerative osteoarthritis of the spine compressing their cervical nerve roots[111], and there are rare reports of an associated spinal cord tumor. Cumulative sun exposure represents another predisposing factor. Due to hypersensitivity of cutaneous nerves, acute UV light exposure can also exacerbate the condition[1,110], and patients living in temperate climates often experience remissions during the fall and winter. Patients may relate that application of ice provides some relief.

Skin examination often reveals a variable number of excoriations, prurigo simplex or nodularis lesions, and even scars localized to the vicinity of the brachioradialis muscle. Evaluation should include a neurologic examination and, based on the results, consideration of cervical spine imaging to exclude myelopathy or tumors. In addition to the treatments noted above, diligent sun protection may be of benefit.

Meralgia paresthetica

Meralgia paresthetica presents with numbness, burning pain, tingling, and/or itching of the anterolateral thigh (Fig. 6.9D)[108]. Allodynia (increased sensitivity to light touch) is another manifestation, but cutaneous findings such as hyperpigmentation are less common than in notalgia paresthetica. Meralgia paresthetica occurs in the territory of the lateral femoral cutaneous nerve, and it results from pressure on this nerve as it passes under the inguinal ligament. Predisposing factors include obesity, pregnancy, prolonged sitting, tight clothing, and carrying heavy wallets in trouser pockets. Much less often, it results from a lumbar radiculopathy.

Cheiralgia paresthetica

Cheiralgia paresthetica is a sensory mononeuropathy of the superficial branch of the radial nerve[108]. Patients report numbness, tingling, or burning involving the dorsoradial aspect of the hand and proximal thumb (see Fig. 6.9A). The cause is usually trauma or pressure, e.g. from a tight wristwatch or handcuffs.

Digitalgia paresthetica

Digitalgia paraesthetica is a sensory neuropathy affecting digital nerves of the fingers and less often the toes[108]. It results from trauma or pressure, e.g. on the fingers from carrying heavy plastic grocery bags or on the toes from long marches or hikes.

Regional Dysesthesias with Burning or Pain

Burning mouth syndrome

Burning mouth syndrome (orodynia) is characterized by burning mucosal pain without clinically detectable oral lesions. The pain is typically bilateral, often involving the anterior two-thirds of the tongue, palate, and lower lip[112]. The buccal mucosa and floor of the mouth are rarely involved. The histology of the affected areas in primary burning mouth syndrome is unremarkable; however, secondary causes may be identified.

The condition typically affects middle-aged or older adults, with a female : male ratio of ~7 : 1[113]. Symptoms can last from a few months to several years. A classification system based on the pattern of disease over time has been described: *type 1* (35%) – absence of symptoms upon awakening, with a gradual increase in severity over the course of the day; *type 2* (55%) – constant burning, both day and night; and *type 3* (10%) – days of remission that follow no identifiable pattern[113].

The evaluation of burning mouth syndrome should include a thorough physical examination to help exclude secondary causes, although the disorder is frequently idiopathic. Localized burning or itch may be the first indication of a malignant lesion (e.g. an oral squamous cell carcinoma). Ill-fitting dentures, oral candidiasis, xerostomia, and contact dermatitis to dental work have been reported as other secondary causes. All prescription and over-the-counter medications should be reviewed to identify any that have xerostomia as a side effect. Additional precipitating factors include iron, zinc, folate, and vitamin B_{12} deficiencies as well as type 2 diabetes mellitus, hypothyroidism, and menopause[114]. Lastly, depression and anxiety are more common in patients with burning mouth syndrome than in pain-free controls[113].

Any underlying disorders should be treated, which may require referral for dental or psychiatric evaluation. In primary burning mouth syndrome, reportedly efficacious treatments include oral tricyclic antidepressants (e.g. amitriptyline, doxepin), topical or low-dose oral clonazepam (start at 0.25 mg and slowly titrate to 1–1.5 mg per day, in 3 divided doses), and gabapentinoids[115]. Antidepressant doses should be low initially and then increased slowly to minimize problematic side effects such as xerostomia and sedation. In case reports and series, successful treatments have included topical antifungal agents (even when cultures were negative), capsaicin, and anesthetics such as lidocaine or dyclonine; in addition, mouthwashes containing various combinations of anesthetics, nystatin, tetracycline, hydrocortisone, and diphenhydramine have been utilized. Cognitive behavioral therapy and α-lipoic acid (600 mg daily) may also improve symptoms[116,117].

Burning scalp syndrome

Burning scalp syndrome (scalp dysesthesia)[118,119] presents with diffuse burning pain, pruritus, numbness, or tingling of the scalp without objective findings. Secondary causes such as seborrheic dermatitis, folliculitis, lichen planopilaris, allergic or irritant contact dermatitis, and dermatomyositis should be excluded and treated if present. Burning scalp syndrome is often associated with underlying depression and anxiety. Like other dysesthesias, it can be treated with gabapentinoids, tricyclic antidepressants, and topical capsaicin[118].

Red ear syndrome

Patients have intermittent episodes of erythema involving one external ear and less often both ears. The redness can persist for minutes to hours and is associated with burning and/or pain. Triggers include heat, cold, and touch. Clinically, this disorder has been likened to erythromelalgia and associated with migraine headaches, but the precise etiology remains unclear. One hypothesis is dysregulation of sympathetic outflow, while some patients have evidence of cervical spine disease. Reported treatments include indomethacin and β-blockers as well as therapies used for other regional dysesthesias.

Dysesthetic anogenital pain syndromes

The most common causes of anal pain are hemorrhoids and fissures. Likewise, genital pain is often related to etiologies such as trauma, infection (e.g. *Chlamydia*, herpes simplex, candidiasis, mpox), and (in men) testicular torsion. Since chronic pain may be a harbinger of malignancy, a thorough evaluation is indicated. However, patients with chronic or recurrent anogenital pain but no detectable abnormalities on physical examination may have a dysesthetic anogenital pain syndrome (Table 6.9). Vulvodynia is discussed in Chapter 73. Of note, anogenital pruritus (see above) can also represent a dysesthetic state.

Trigeminal neuralgia and trigeminal trophic syndrome

Trigeminal neuralgia (tic douloureux) is characterized by recurrent paroxysms of sharp pain lasting seconds to minutes and radiating into the territory of one or more of the trigeminal sensory divisions. The pain is usually unilateral (most often right-sided) and described as a stabbing, burning, or shocking sensation. Attacks occur as often as several times per day or as infrequently as a few times per month. Potential triggers include touching or washing the face, brushing of teeth, eating, and talking. Cutaneous and neurologic examinations are

DYSESTHETIC ANOGENITAL PAIN SYNDROMES	
Syndrome	**Clinical history**
Levator ani syndrome	Brief intermittent burning pain or tenesmus of the rectal or perineal area. Aggravated by sitting or elimination
Proctalgia fugax	Sudden stabbing pain in the perirectal area. Awakens patient from sleep
Coccydynia	Intermittent or persistent pain, usually burning type, localized to the coccyx
Male genital pain syndrome	Intermittent, continuous, or episodic pain during penetration, ejaculation, micturition, or exercise
Koro syndrome	Psychogenic disorder characterized by acute anxiety, fear of death, and sensations that the genitalia are inwardly retracted and (variably) burning pain

Table 6.9 Dysesthetic anogenital pain syndromes. Vulvodynia is discussed in Chapter 73.

Downloaded for Anonymous User (n/a) at Egyptian Knowledge Bank from ClinicalKey.com by Elsevier on March 10, 2024. For personal use only. No other uses without permission. Copyright ©2024. Elsevier Inc. All rights reserved.

typically normal; if neurologic findings are present, the possibility of an underlying tumor or multiple sclerosis should be considered.

MRI should be performed to exclude secondary causes of trigeminal neuralgia ("painful trigeminal neuropathy"), such as multiple sclerosis, trauma, or a tumor. In ~80%–90% of patients with trigeminal neuralgia, high-resolution MRI with MRA demonstrates compression of the trigeminal nerve root by a vascular loop (referred to as the "classic" form)[120]. Rare familial forms have been linked to variants in genes encoding voltage-gated ion channels and transient receptor potential channels[121,122].

Regardless of etiology, carbamazepine (200–1200 mg daily) and oxcarbazepine (300–1800 mg daily) are considered first-line therapies for trigeminal neuralgia, providing relief in ~90% of patients[122]. Additional treatment options include gabapentinoids, lamotrigine, and baclofen. Botulinum toxin A injections may also be of benefit[123]. In refractory disease, surgical interventions such as microvascular decompression and ablative procedures (e.g. gamma knife radiosurgery) can be employed.

Trigeminal trophic syndrome is a self-induced ulcerative condition of the central face that classically involves the nasal ala[124,125]. Patients characteristically present with a small crust that develops into a crescentic ulcer, which may gradually extend to involve the cheek and upper lip (Fig. 6.10). The self-mutilation is triggered by dysesthesia together with hypesthesia, both resulting from damage to the sensory portion of the trigeminal nerve. The nasal tip, which is supplied by the external nasal branch of the anterior ethmoidal nerve (see Ch. 142), is typically spared. The underlying nerve damage is most often iatrogenic due to therapeutic ablation for trigeminal neuralgia; other causes include stroke, herpes zoster, trauma, and craniofacial surgery[125]. *Cervical trophic syndrome* represents a similar condition in which dysesthesia and self-mutilation occur in a cervical distribution[126].

The differential diagnosis of a non-healing facial ulcer includes malignancies (e.g. basal cell or squamous cell carcinoma, nasal NK/T cell lymphoma), infections (e.g. chronic herpes simplex, *Leishmania* spp., dimorphic fungi), inflammatory disorders (e.g. granulomatosis with polyangiitis, pyoderma gangrenosum), and factitial disease (see Table 45.3). Treatment of trigeminal trophic syndrome is challenging. Medications such as carbamazepine, gabapentinoids, amitriptyline, and pimozide have limited effectiveness. Protective barriers worn at night and patient education are important measures. Surgical repair of the defect(s) with innervated skin flaps provides the greatest chance for resolution[124,125].

Fig. 6.10 Trigeminal trophic syndrome. A Ulceration with serohemorrhagic crusting on the nasal ala, as well as excoriations, superficial ulcers, and scars on the upper lip, chin, and cheek. **B** Ulceration localized to the nasal ala and adjacent cheek. *A, Courtesy Lorenzo Cerroni, MD; B, Courtesy Edward Cowen, MD.*

Complex regional pain syndrome (reflex sympathetic dystrophy)

Complex regional pain syndrome (CRPS; reflex sympathetic dystrophy) is characterized by continuing regional pain that is seemingly disproportionate to the usual course following trauma or other insults; evidence of damage to peripheral nerves is present in a subset of patients. The upper extremities, especially the hands (Fig. 6.11), are most commonly affected, but the distal lower extremities may also be involved. Regional insult to nociceptive terminals results in a signal cascade that ultimately amplifies the pain response in the CNS. The disease was traditionally described as progressing through several stages, which were thought to be due to autonomic nervous system dysfunction[119].

Signs and symptoms within the affected region include burning pain, hyperalgesia, allodynia, vasomotor dysfunction (e.g. edema, erythema, livedo reticularis, cyanosis), hypertrichosis, hyperhidrosis, nail dystrophy, motor dysfunction, and eventually atrophy. Patients suspected to have CRPS should be referred to a neurologist for further evaluation and treatment. Physical and occupational therapy represent first-line treatment options. Therapies may be directed toward interruption of the autonomic nervous system, but they often have limited efficacy[127].

Congenital Insensitivity to Pain and Related Conditions

Congenital insensitivity to pain belongs to a group of hereditary sensory and autonomic neuropathies (HSAN) in which neurons fail to develop or degenerate[128] (Table 6.10).

Fig. 6.11 Complex regional pain syndrome with scaling and erosions of the fingertips. *Courtesy Kalman Watsky, MD.*

Downloaded for Anonymous User (n/a) at Egyptian Knowledge Bank from ClinicalKey.com by Elsevier on March 10, 2024. For personal use only. No other uses without permission. Copyright ©2024. Elsevier Inc. All rights reserved.

CONGENITAL INSENSITIVITY TO PAIN (CIP) AND RELATED HEREDITARY SENSORY AND AUTONOMIC NEUROPATHIES (HSANs)			
Features of CIP: • Oral self-mutilation due to biting of lips, tongue, and buccal mucosa • Biting of fingertips resulting in ulceration and eventual autoamputation • Bruises, cuts/wounds, burns, skin infections, joint dislocations, and fractures with resulting scars and deformities • Immunohistochemical staining for neuronal markers (e.g. PGP-9.5) shows almost complete absence of innervation to sweat glands, blood vessels, and arrector pili muscles within the skin			
HSAN type, disorder name	**Gene(s) (inheritance)**	**Protein**	**Additional clinical features**
II, Morvan disease	*WNK1, FAM134B, KIF1A* (AR)	WNK lysine deficient protein kinase 1, FAM134B, kinesin family member 1A	• Hyporeflexia, hypotonia • GI dysmotility • Acral anhidrosis, episodic hyperhidrosis
IID, CIP	*SCN9A** (AR)	Sodium voltage-gated channel α subunit 9	• Variable hearing impairment, anosmia • Variable hypohidrosis
III, familial dysautonomia (Riley–Day syndrome)	*IKBKAP* (AR)	Inhibitor of κ light polypeptide gene enhancer in B cells, kinase complex-associated protein	• Ashkenazi Jewish patients • Hyporeflexia, hypotonia • Less impaired pain/temp perception, acral sparing • No emotional tears • Postural hypotension, episodic hypertension • Vomiting crises with blotchy erythema of skin • Absent lingual fungiform papillae
IV, CIP with anhidrosis	*NTRK1* (AR)	Neurotrophic receptor tyrosine kinase 1 (high-affinity NGF receptor)	• Complete lack of pain (including visceral) and temp sensation, but normal touch and reflexes • Anhidrosis with febrile episodes • Intellectual disability • Increased susceptibility to staphylococcal infections
V, CIP	*NGF* (AR)	Nerve growth factor	• As in IV but variable anhidrosis and intellectual disability
VI	*DST* (AR)	Dystonin	• Similar to III
VII, CIP with GI dysfunction and hyperhidrosis	*SCN11A** (AD)	Sodium voltage-gated channel α subunit 11	• Diarrhea, constipation • Hyperhidrosis, pruritus • Muscular weakness
VIII, CIP	*PRDM12* (AR)	PR/SET domain 12	• Variable hypohidrosis and reduced tearing
*Gain-of-function mutations can result in hereditary neuropathies presenting with burning/episodic pain or (for *SCN9A*) erythromelalgia.			

Table 6.10 Congenital insensitivity to pain (CIP) and related hereditary sensory and autonomic neuropathies (HSANs)[128]. HSAN type I includes several autosomal dominant disorders with onset typically in later childhood or adulthood; features include motor as well as sensory neuropathy, dysesthesia with "lightning" pains, and variable hearing loss and hyperhidrosis. AD, autosomal dominant; AR, autosomal recessive; FAM134B, family with sequence similarity 134, member B; PGP-9.5, protein gene product 9.5; temp, temperature.

TREATMENT

Thus far, no antipruritic drug is indicated for relief of itch irrespective of its origin. Thus, individualized management of each patient and pruritic disease process is necessary[8,10]. General measures and specific treatments that can be selected according to the patient's complaints are discussed below and summarized in Table 6.11.

General Measures

Patient education and elimination of provocative factors are important, including wearing soft breathable clothing (i.e. no wool or rough fabrics), avoiding excessive bathing (lukewarm baths or showers with mild synthetic detergents [syndets]), using emollients on a daily basis with application immediately after bathing, and managing dermographism if present. Patients can be taught methods of interrupting the itch–scratch cycle, such as application of a cold washcloth or gentle pressure. Controlled physical exercise, relaxation therapy, and minimization of exposure to heat as well as reduction of stress and anxiety are beneficial. Avoid telling patients "don't scratch" given how difficult it is to follow this advice.

Topical Treatment

A large variety of topical compounds that have antipruritic properties are available, including corticosteroids, anesthetics (e.g. pramoxine, polidocanol), and counterirritants (e.g. menthol, camphor).

Topical anesthetic agents (e.g. lidocaine/prilocaine) decrease pain and pruritic sensations and they may relieve tingling and dysesthesias[129]. Topical doxepin has demonstrated antipruritic effects in atopic dermatitis and other eczematous dermatoses, including lichen simplex chronicus, nummular eczema, and contact dermatitis[130]. However, side effects such as drowsiness can occur when it is applied to large portions of the body or in young children. In addition, the possibility of allergic contact dermatitis to topical doxepin and potentially systemic contact dermatitis with subsequent oral administration should be considered. Compounded topical cromolyn sodium has been found to relieve allergen- and histamine-induced pruritus without blocking wheal formation, suggesting a mechanism other than prevention of mast cell degranulation.

Capsaicin is a naturally occurring alkaloid found in many species of the nightshade family (Solanaceae), especially chili peppers. Capsaicin enhances the release and secondarily inhibits the re-accumulation of neuropeptides such as substance P. It also transiently destroys intraepidermal nerve fibers. Topical capsaicin has successfully been used in several dermatologic disorders, although it is not beneficial in atopic dermatitis[131]. Concentrations usually range from 0.025%–0.1%, and it needs to be applied three to six times daily for maximal effect. While capsaicin can be safely applied to large areas of skin[132], and its side effects of stinging, burning, pain, erythema, and irritation decrease with continued use, it is typically utilized to treat localized pruritus.

Topical tacrolimus and pimecrolimus have both anti-inflammatory and antipruritic effects[133] and are successfully used in pruritic conditions including atopic dermatitis (see Ch. 128). Burning and erythema at the application site are the most commonly reported adverse events. Rapid improvement of pruritus has also been reported in patients with atopic dermatitis treated with topical ruxolitinib[134].

Downloaded for Anonymous User (n/a) at Egyptian Knowledge Bank from ClinicalKey.com by Elsevier on March 10, 2024. For personal use only. No other uses without permission. Copyright ©2024. Elsevier Inc. All rights reserved.

GENERAL MEASURES FOR THE TREATMENT OF PRURITUS AND DYSESTHESIA
Skin care
• Twice daily application of a moisturizing cream or ointment • Warm (not hot) baths/showers ≤ once daily, with minimal use of a mild soap/non-soap cleanser, and followed immediately by moisturizer application; especially in winter, consider limiting use of soap to odorous regions such as the axillae and anogenital area • Avoid wool and other rough fabrics • Keep nails cut short
Topicals
• *Cooling agents/counterirritants*: e.g. menthol, camphor • *Capsaicin* • *Anesthetics*: e.g. pramoxine, lidocaine, prilocaine, polidocanol, palmitoylethanolamine • *Anti-inflammatory agents*: corticosteroids, calcineurin inhibitors, Janus kinase (JAK) inhibitors
Systemic medications
• *Antihistamines*: especially if there is a component of dermographism or urticaria; otherwise limited efficacy beyond sedative effects • *Gabapentinoids*: gabapentin, pregabalin • *Antidepressants:* SSRIs (e.g. fluoxetine, paroxetine, sertraline, venlafaxine), tricyclics (e.g. amitriptyline, doxepin), mirtazapine • *Opioid antagonists/agonists:* e.g. naltrexone, butorphanol nasal spray, nalfurafine, nalbuphine, naloxone • *Targeted immune modulators* (especially for atopic dermatitis and prurigo nodularis): e.g. dupilumab, tralokinumab (anti-IL-4/-13); nemolizumab (anti-IL-31); JAK inhibitors • *Other:* thalidomide (especially for prurigo nodularis), aprepitant (NK1 receptor antagonist)
Physical modalities
• *Phototherapy*: UVB (broadband or narrowband), PUVA, UVA, UVA-1 • Acupuncture
Psychological approaches
• Behavior modification therapy, biofeedback • Support groups

Table 6.11 General measures for the treatment of pruritus and dysesthesia. NK1, neurokinin 1; PUVA, psoralen plus UVA; SSRI, selective serotonin reuptake inhibitor.

Systemic Treatment

Systemic drugs with antipruritic properties often act centrally and have sedating effects. With progress in understanding the pathophysiology of pruritus, treatments targeting specific mediators and pathways have become possible, such as κ-opioid receptor agonists (e.g. difelikefalin, nalfurafine) and/or μ-opioid receptor antagonists (e.g. naloxone, naltrexone); NK1 receptor antagonists (e.g. aprepitant); and antibodies targeting IL-31 signaling (e.g. nemolizumab)[135]. However, placebo responses in pruritus patients are often substantial (e.g. 66% in one study)[10], demonstrating the powerful central modulation of pruritus. Placebo-controlled studies are therefore essential to evaluate drugs with potential antipruritic effects.

Physical Treatment Modalities

UV light therapies (broadband and narrowband UVB, UVA, UVA-1, UVA/UVB, PUVA) have beneficial effects in pruritic inflammatory dermatoses, maculopapular cutaneous mastocytosis, renal and cholestatic pruritus, pruritus associated with HIV infection, aquagenic pruritus, and prurigo nodularis[102].

Transcutaneous electronic nerve stimulation has been reported as beneficial in different types of pruritus, such as that found in aged skin. This may be partially a placebo effect as it tends to decline with continued therapy[10]. Acupuncture has also been described as a successful treatment for pruritus vulvae, allergic contact dermatitis, and renal pruritus. Acupuncture was reported to decrease experimental histamine-induced pruritus but had no effect on maximal pruritus intensity or onset time[10].

Psychological Approaches

Pruritus may be precipitated, prolonged, or enhanced by a number of stress-related mediators such as histamine and neuropeptides. There are also multiple secondary psychosomatic mechanisms through which pruritus may be generated or exacerbated, e.g. sweating, alterations in cutaneous blood flow, and scratching[1]. Of note, psychological factors are thought to be able to diminish as well as augment pruritus.

Studies have shown that group psychotherapy, behavioral therapy, controlled physical exercise, support groups, and biofeedback can help to stop scratching and improve quality of life[1,10].

Additional figures available in our eBook (see inside front cover for access code).

eFig. 6.1 Atopic dermatitis. A Multiple lesions of prurigo nodularis. **B** Multiple linear excoriations are seen on the leg.

Downloaded for Anonymous User (n/a) at Egyptian Knowledge Bank from ClinicalKey.com by Elsevier on March 10, 2024. For personal use only. No other uses without permission. Copyright ©2024. Elsevier Inc. All rights reserved.

eFig. 6.2 Prurigo nodularis. A, B Numerous excoriated papules and nodules on the back, with sparing of the mid upper back ("butterfly sign"). **C** Crusted papules on the upper arm. **D** Papulonodules with central ulcerations due to picking admixed with scars. *D, Courtesy Kalman Watsky, MD*.

eFig. 6.3 Lichen simplex chronicus (LSC). A LSC of the scrotum; secondary pigmentary changes are more common in patients with darkly pigmented skin. **B** LSC on the neck of a man; note the increased skin markings. *A, Courtesy Louis Fragola, MD*.

Downloaded for Anonymous User (n/a) at Egyptian Knowledge Bank from ClinicalKey.com by Elsevier on March 10, 2024. For personal use only. No other uses without permission. Copyright ©2024. Elsevier Inc. All rights reserved.

eFig. 6.4 Xerosis. A Xerosis and scratching in a patient with renal insufficiency undergoing hemodialysis. **B** Extreme xerosis associated with pruritus in an HIV-infected patient.

eFig. 6.5 Pemphigoid nodularis. Multiple crusted lesions and scars are evident. Bullous pemphigoid is often intensely pruritic and may not present with intact vesiculobullae. *Courtesy Jeffrey P. Callen, MD*.

eFig. 6.6 Pruritus from sensory neuropathies. A Notalgia paresthetica presenting with hyperpigmented patches with lichenification on the infrascapular and suprascapular right back. **B** Brachioradial pruritus. The affected area is outlined by ink.

Downloaded for Anonymous User (n/a) at Egyptian Knowledge Bank from ClinicalKey.com by Elsevier on March 10, 2024. For personal use only. No other uses without permission. Copyright ©2024. Elsevier Inc. All rights reserved.

eFig. 6.7 Trigeminal trophic syndrome. Erosions and ulcerations with hemorrhagic crusts favor the ala nasi (**A, B**). Obvious linear excoriations are seen in the second patient **(B)**. *Courtesy Kalman Watsky MD.*

Downloaded for Anonymous User (n/a) at Egyptian Knowledge Bank from ClinicalKey.com by Elsevier on March 10, 2024. For personal use only. No other uses without permission. Copyright ©2024. Elsevier Inc. All rights reserved.